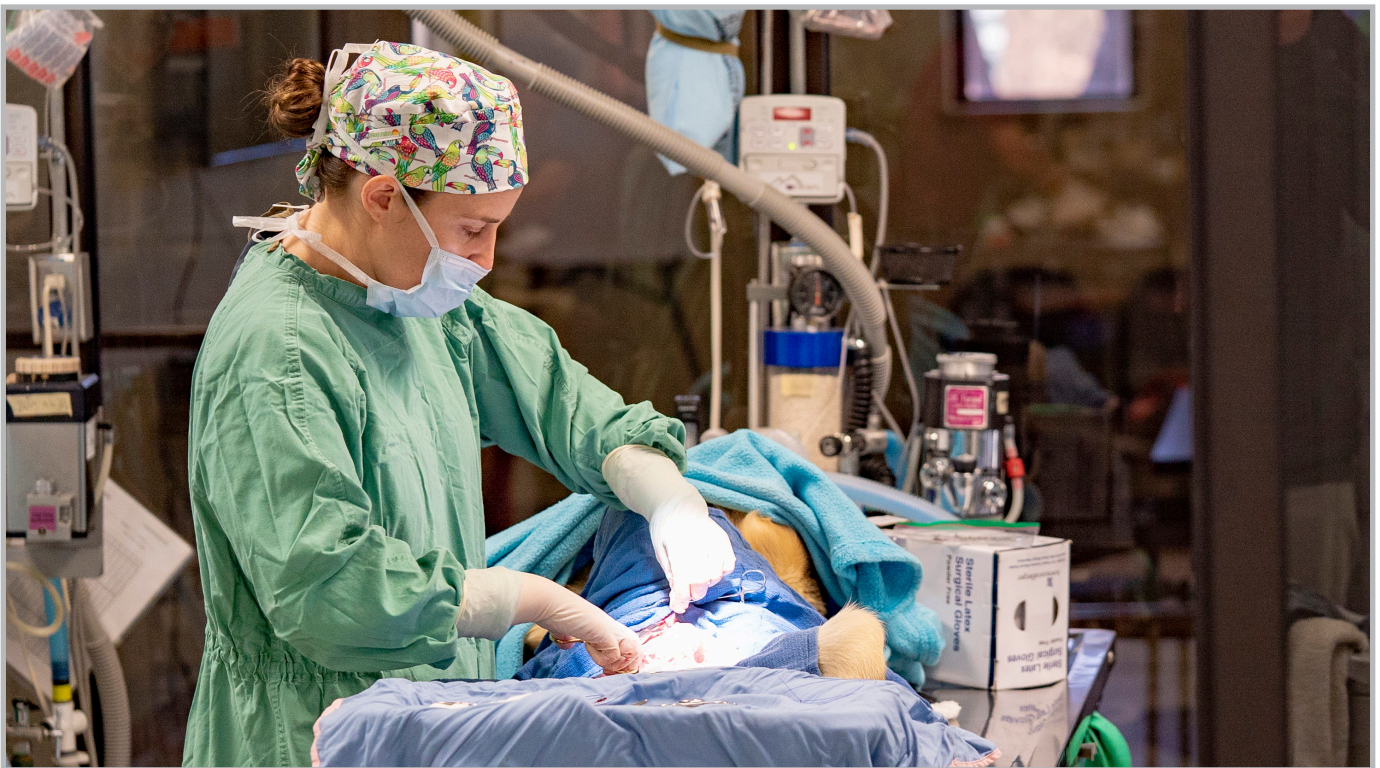

Spay/Neuter Training Reference Guide for Veterinarians



**A resource guide for your on-site
ASPCA Spay/Neuter Alliance training program.**

Table of Contents

Chapter 1: Procedural Overview	3
Chapter 2: Tips for Successful Surgical Event	4
Chapter 3: Anatomy Review	5
Chapter 4: Incision Placement	6
Chapter 5: Instructional Videos	7
Chapter 6: Approach for Scrotal Puppies	8
Chapter 7: Scoring Tattoo	9
Chapter 8: Ear-tipping	10
Chapter 9: FAQs	11
Chapter 10: Resources & Research	13

Chapter 1: Procedural Overview



The surgical procedure itself should maintain a routine sequence of events to assure that each patient is receiving the same standard of care. The surgeon should ensure that the technicians follow a thorough protocol for surgical preparation of the patients, including, but not limited to, complete clip, debris removal, surgical scrub, and bladder expression in females.

As the surgeon approaches the patient in the operating room, a generally accepted practice would be to double-check the status of the patient. Parameters include:

- The patient should be properly connected to the anesthesia machine
- Oxygen and isoflurane levels should be appropriate
- The monitoring equipment should be operational
- It should be confirmed that the patient is at the correct plane of anesthesia and the veterinary surgeon must verify sex of the patient, especially with cats
- Finally, it should be noted that the patient is in proper position for the surgery and that the light source is directed toward the incision site. At this point, the veterinary surgeon may proceed.

The patient is draped in with three or four quarter drapes, with or without a fenestrated drape. Any combination of the above is considered acceptable, as long as there is an appropriate barrier to prevent contamination of the surgical site.

Chapter 2:

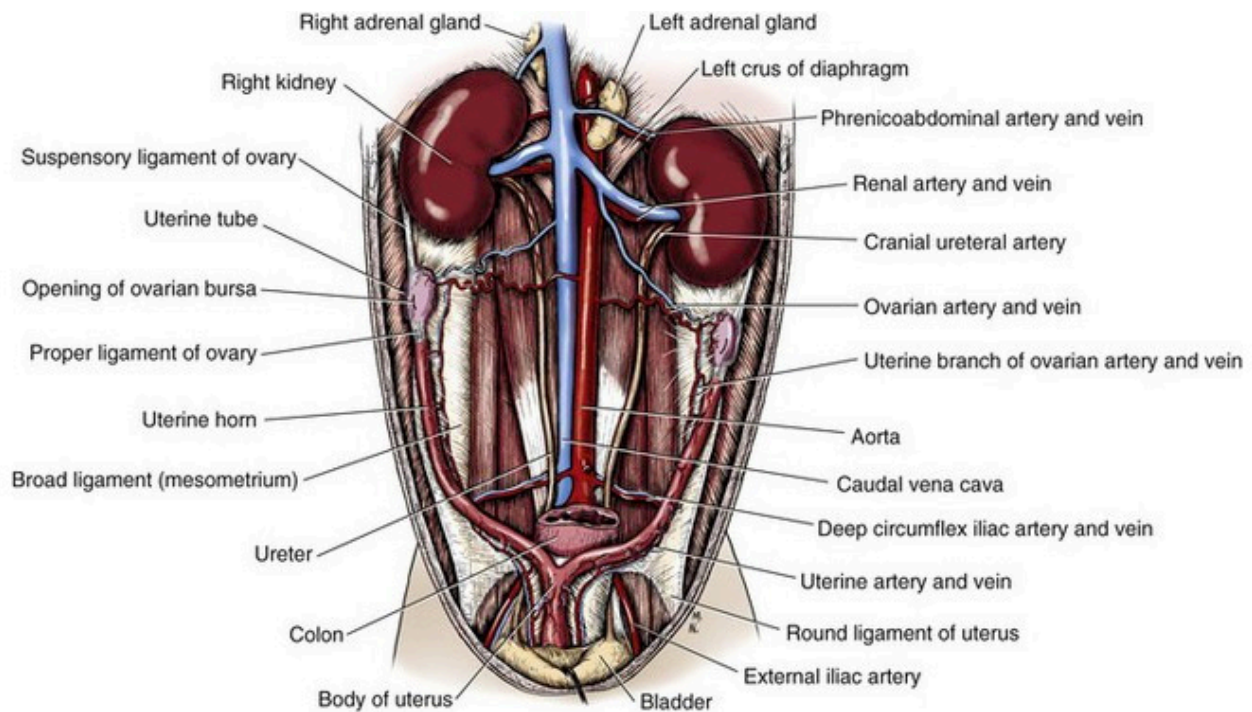
Tips for Successful Surgical Event

The most important factor in proper surgical technique is that meticulous, careful tissue handling be observed in any procedure. The following additional points will also be emphasized:

- A rigorous ability to maintain sterile technique at all times;
- Incision placement and its importance;
- Removing minimal subcutaneous tissue, which will reduce dead space and facilitate efficient entry into the abdomen;
- Proper and gentle spay hook technique;
- Cutting the ovary away prior to ligation (female dog)/pedicle tie (female cat);
- Using a strangle knot and setting using the carmalt;
- Four throws (two square knots) on all sutures - this technique has been proven to decrease the incidence of dehiscence, and must always be used;
- Large bites on the linea alba: include at least 5-to-8 mm rectus tissue in the linea closure in cats and up to 10-to-12 mm in large dogs. A cruciate suture pattern with a *surgeon's throw* is used to decrease tension and speed closure time;
- No crushing sutures in closing - linea and subcutaneous tissue should be snugly and completely closed but never crushed;
- Linea and subcutaneous tissue should be closed with polydioxanone (PDS II) suture (see Chapter 9 for discussion on suture material);
- At least three-layer closure: linea, subcutaneous, and subcuticular, plus skin glue (staples are used if skin edges are not apposed);
- Skin edges should be properly apposed - never allow one side to flap over the other or extend above the other. Skin glue should not be applied between the skin edges, but rather on the surface after apposing the edges. Skin glue should only be used as a protective barrier, and never used for "added strength," or used in place of properly placed skin sutures;
- A tattoo is applied to all patients to ensure no future unnecessary anesthesia or surgery (see Chapter 7).

Chapter 3: Anatomy Review

Anatomy of the Female Reproductive Tract



This illustration depicts the anatomy of the female reproductive tract. Take note of the position and location of the ovaries, the attachment of the broad ligament, and the location at the uterine body in relation to the bladder.

Courtesy: Evans HE, de Lahunta A: Miller's anatomy of the dog, ed 4, St Louis, 2013, Saunders/Elsevier.

Chapter 4: Incision Placement

The incision placement will obviously vary with both the sex and the species of the patient. We have also determined that varying the incision placement depending on the age of the patient can improve the efficiency of the entire procedure.

- Incisions in adult female dogs are generally placed directly caudal to the umbilicus (*Figure 1*)
- Incisions in pediatric female dogs are generally placed approximately halfway between the umbilicus and pubis (*Figure 2*)
- Incisions in adult or pediatric female cats are also placed approximately halfway between the umbilicus and pubis

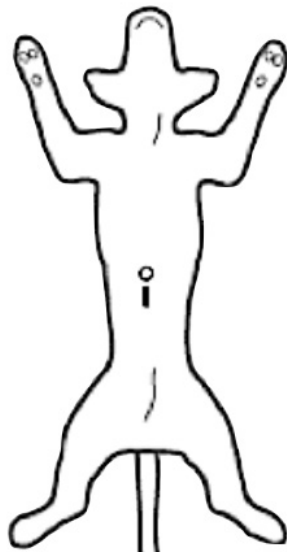


Figure 1. Adult dog incision placement

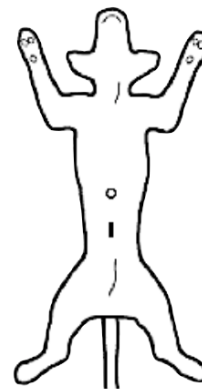
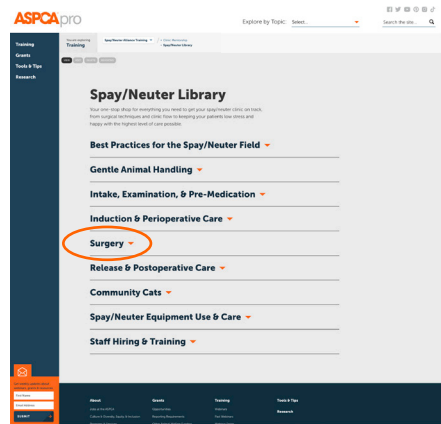


Figure 2. Feline/pediatric dog incision placement

- In female dogs, there are several factors which will influence the craniality of your incision placement. The older, larger, heavier, and deeper-chested a dog is, the more cranial the incision should be centered.
- Adult male dogs are neutered with either a pre-scrotal or scrotal incision (however, in pediatric male dogs, the routine approach is scrotal)

Chapter 5: Instructional Videos

Our catalog of instructional videos can be found under the surgery section of www.aspcapro.org/spayneuterlibrary, including:



General

- Draping Techniques During Spay/Neuter Surgery
- Obtaining Suture & Threading a Needle
- Spay/Neuter Tattoo Application

Female Dogs

- Spay Incision Placement
- Spay Hook Use
- Canine Suspensory Ligament
- Ovarian Cutaway & Ligature Placement
- Breaking the Broad Ligament
- Gravid Uterine Artery Ligation)
- Strangle Knot
- Closure for Female Dogs

Male Dogs

- Incision Placement
- Modified Puppy Scrotal Approach
- Strangle Knot

Female Cats

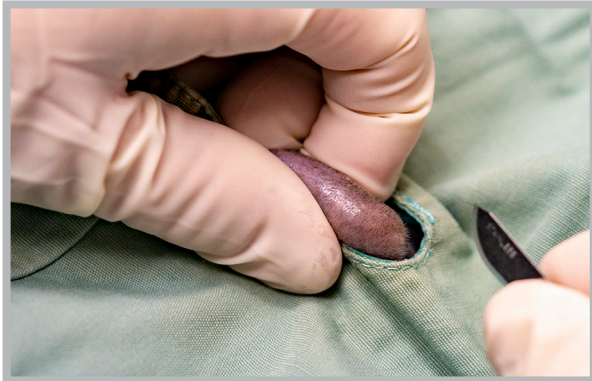- Spay Incision Placement
- Closure for Female Cats
- Spay Hook Use

Male Cats

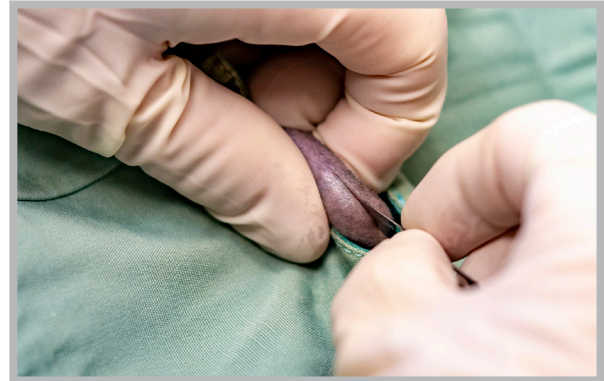
- Strangle Knot

Chapter 6: Approach for Scrotal Puppies

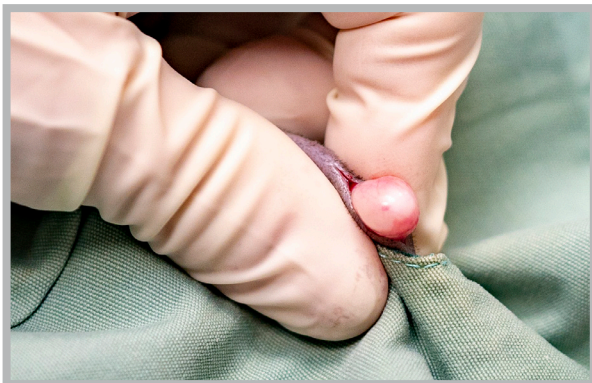
Surgical Field: Note the entire scrotum has been clipped and prepped for surgery.



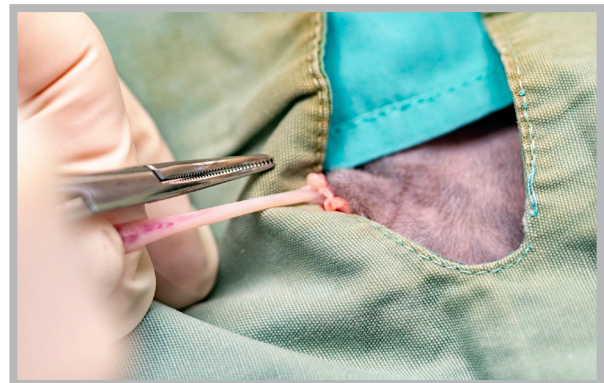
1. The surgeon grasps one testicle, positioning it such that the median raphe is elevated and exposed.



2. The incision is made on the median raphe. Both testicles will ultimately be removed through this same incision centrally located in the scrotum. This approach may be used in both pediatric puppy and feline castrations.



3. The testicle is exteriorized using gentle traction.



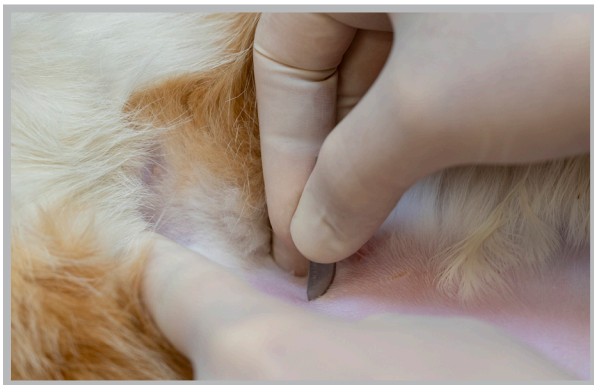
4. The cord is stripped of any excess tissue or fat. Open or closed technique may be used according to surgeon's preference.

A **cord tie** or **figure 8 knot** is used to ligate the spermatic cord according to surgeon's preference. For puppies, the general rule of thumb for determining if the cord can be ligated using one of these techniques is as follows: If the scrotum is not pendulous and the testicular size is no larger than that of a mature tomcat, then these techniques are appropriate. For larger testicles, suture is recommended for ligation. The procedure is repeated for the second testicle and the wound is left open to heal by second intention.

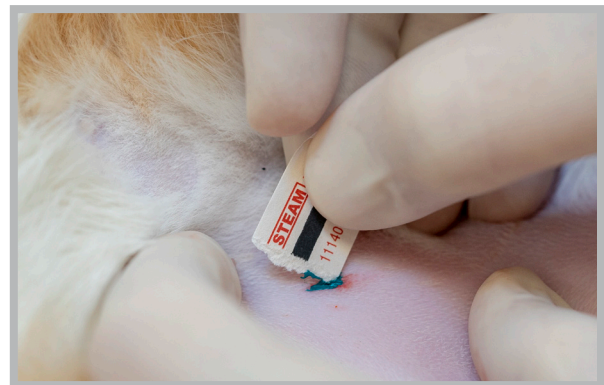Chapter 7: Scoring Tattoo

Tattoos are used as an indicator that an animal has been spayed or neutered. This is sometimes called a scoring tattoo, since the skin is scored with a scalpel blade and green paste is then applied, which is a more obvious color, especially on animals with darkly pigmented skin. It is a simple, cost-effective method to ensure the animal never has an unnecessary future exploratory to determine reproductive status. This closure technique prevents patients from licking the tattoo and developing a temporary case of “green tongue” in recovery.

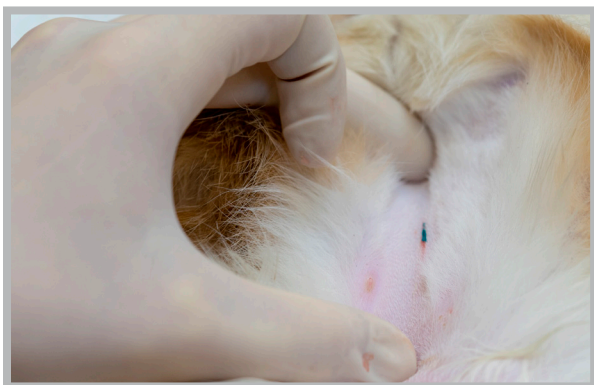- Both female dogs and cats should have the tattoo placed near the incision site
- Male dogs should have the tattoo placed in the pre-scrotal area
- Male cats should have the tattoo placed where an incision would be searched for in a female cat (as neutered male cats are often misjudged as females)



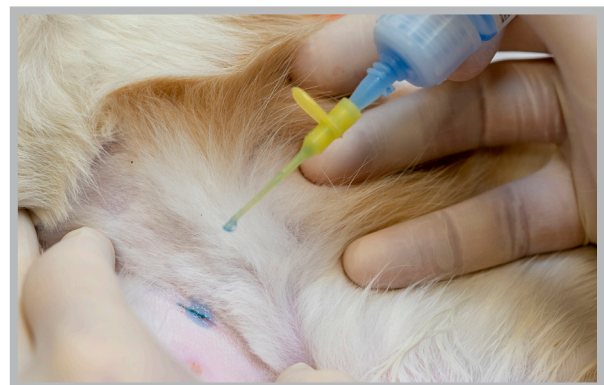1. The skin is scored (~1 cm) with a scalpel blade.



2. Paste is applied to the scored tissue.



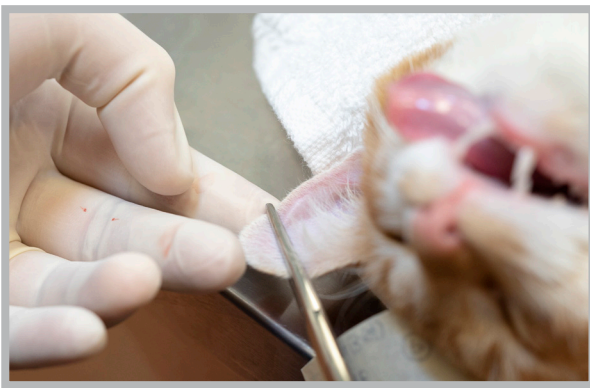
3. The skin edges are slightly inverted.



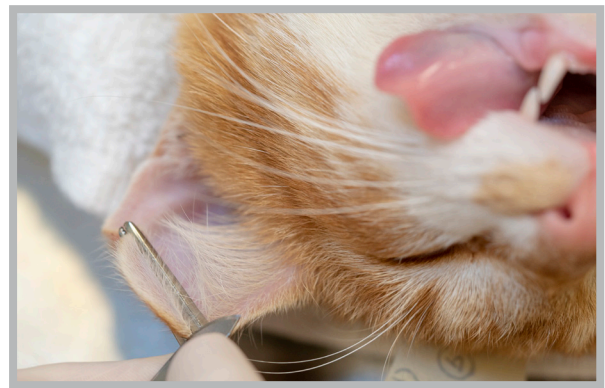4. A drop of tissue adhesive is applied on top of the skin for closure.

Chapter 8: Ear-tipping

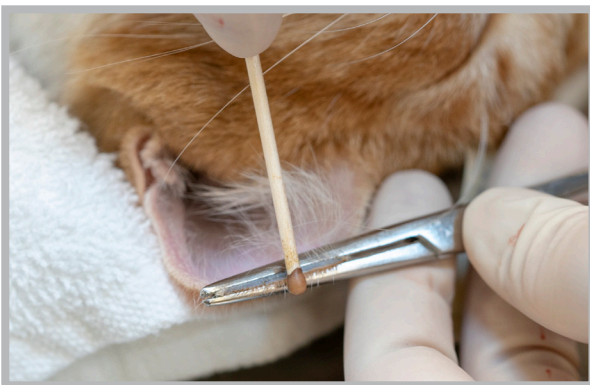
Removing the tip of the ear in community cats is a universal sign permanently identifying the cat as having been spayed or neutered.




1. A straight hemostat is placed perpendicular to the long axis of the pinna, exposing proportionately approximately 1/3 of the ear tip.



2. The ear tip is removed *using the straight scissors or scalpel blade* to cut over the edge of the hemostats.



3. The hemostats are left in place until hemostasis occurs. A silver nitrate stick can encourage hemostasis.



4. Proper appearance of an ear after being cropped. Note the distinctive straight edge that is easily recognizable from a distance.

Chapter 9:

Frequently Asked Questions

Do you prefer clipping or plucking for cat castrations?

We clip for all surgical procedures, including cat castrations. While plucking is an acceptable form of hair removal, we choose to clip these patients to give us a broader hair-free surgical field, which can decrease contamination, particularly in long-haired cats. For us, clipping is also a faster way of preparing the surgical site.

Can I focus on certain procedures during my training?

While we make every effort to provide the types of surgeries that you would like to perform, this is ultimately up to the discretion of your instructor and the types of animals that we have come through the clinic. If your instructor feels that you need work in a certain area, s/he will let you know and will work with you to also incorporate those types of cases. Keep in mind that some cases (such as cryptorchids) are not always available.

Can I take pictures/video of procedures, equipment, setup, etc.?

To protect our patients, we prefer you to NOT take pictures while in the surgical area. If there is a specific piece of equipment you would like a photo of, we may have it already available to view on [ASPCApr.org](https://www.aspcapro.org), along with purchasing information. If not, we'd be happy to take a photo for you.

Why do you use polydioxanone (PDS II) suture? Why reels instead of packets?

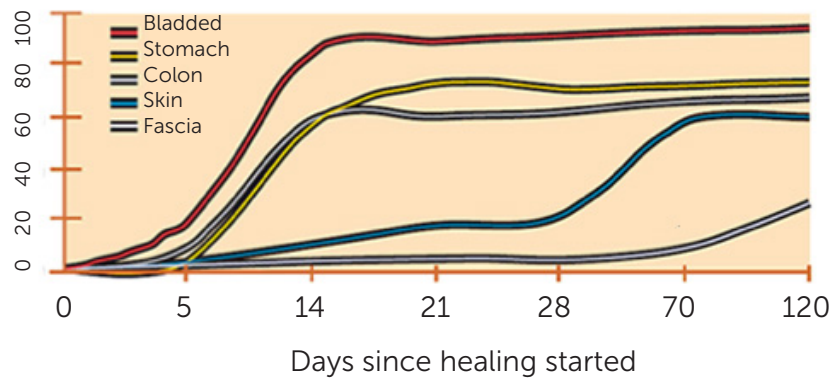
Simply put, it is the best choice for the high-quality, high-volume spay/neuter (HQHVSN) arena. Suture on a reel is much less expensive than swaged-on suture (suture with the needle attached), and PDS II has the balance of strength and decreased reactivity that is needed in an absorbable suture that is to be used on a large, varied population of cats and dogs. Keep in mind that the body wall takes 2-4 weeks to heal completely after surgery. When you look at the chart below of commonly used suture types, you will see that PDS II retains its strength longer than plain catgut, chromic catgut, and Monocryl™. Catgut's short duration of strength and high level of reactivity makes it unsuitable for use in the HQHVSN setting (even on the pedicles, uterine stump, and testicular cords).

Although Monocryl™ has less reactivity in subcutaneous tissue than PDS II, its short duration of strength retention makes it a less than ideal choice for anything but young, fast-healing patients.

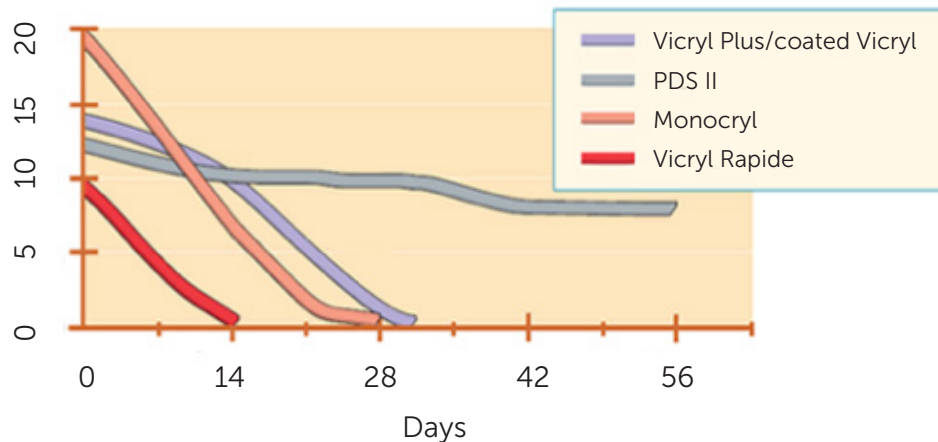
Why do you use PDS suture (cont)?

Suture	Strength Retention Profile	Absorption Time
Catgut (plain)	90% lost in 7-10 days	70 days
Chromic catgut	90% lost in 21-28 days	90 days
Monocryl™	70% lost in 14 days	100 days
PDS II	70% lost in 42 days	180 days

% Strength of unwounded tissue



Actual strength (lbs)



Chapter 10: **Resources & Research**

- [Visit ASPCApro for a full list of resources and research that supports our protocols.](#)

