

Foster Home Based Ringworm Treatment Protocol for Kittens – LA Foster Program

January 2020

Goal: To provide a streamlined protocol for a point-of-care diagnosis of ringworm; to provide a treatment and management protocol that increases foster compliance in care-giving; and to ensure ringworm positive animals are safely and effectively treated and socialized while reducing the chances of zoonotic transmission in a private home.

Background: Despite its name, ringworm is a fungal infection that causes alopecia/crusts/redness of the skin. It is contagious to other animals, as well as to people. The most common ringworm species affecting cats is *Microsporum canis*.

Transmission: Primarily through direct contact with an infected animal. Secondly through fomite transmission. Rarely through environmental contamination. However, it's important to note that ringworm is very durable in the environment and can readily contribute to fomite transmission through contaminated grooming tools, contaminated bedding, or by human clothing and hands.

Recognizing infected individuals:

A combined technique using Wood's lamp and direct examination can provide point-of-case diagnosis for most ringworm cases. Ringworm PCR may be needed for highly suspect cases that have suspicious lesions and/or a known history of ringworm exposure but are negative on Wood's lamp and direct examination.

Visual examination of the fur and skin – focusing on the face, toes, inner and outer ears, and paws - followed by a Wood's lamp examination is the first step. Following up with a direct examination of fur to document active infection on suspect animals is the second step.

Lesions in the fur or skin seen on visual exam which are suspicious for ringworm infection include:

- Fur loss or broken, brittle hairs or whiskers
- Red, inflamed skin
- Scaling or crusting (“flakiness”) or scabs of the skin
- Itchy skin, especially where lesions are location

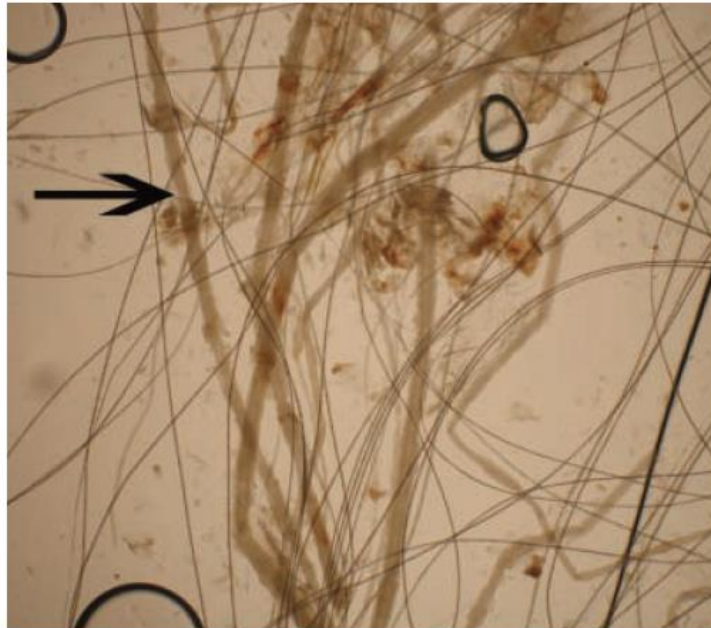
Wood's lamping to look for *Microsporum canis*:

- Wear gloves. In a dark room, plug in the lamp and allow your eyes to adjust to the darkness.
- Perform in a dark room with two people – one to hold and one to look - for accuracy.
- Be sure to examine the entire animal, but focus on ears, muzzle, around the eyes, whiskers and feet.
- With a true ringworm infection, the fungus is infecting the inside of the hair.
 - o The entire hair shaft, including the intrafollicular portion, should glow apple green - not the skin - and attempts to wipe away the glow will not succeed.
 - o Always peel away glowing crusts or scabs and look for glowing hairs (including stubble) under.
 - o Glowing crusts do NOT confirm ringworm infection.
- False positives can be generated by several non-infectious causes, including medication residue (e.g. doxycycline, terramycin, and pyrantel), carpet or towel fibers, dander, dust, urine, crusts/scabs on skin.
- Keep a positive control of a Wood's lamp positive hair sample nearby for cross reference.

Direct examination (trichogram) of Wood's lamp positive hairs:

- Pluck glowing hairs in direction of growth.
- Mount hair and scales in mineral oil.
 - o Can add a drop of methylene blue to mineral oil for facilitated visualization.

- Use Wood's lamp to help locate glowing hairs on slide, then reposition the slide to bring these hairs into field of vision.
- Under 4x or 10x magnification, look for hairs that are pale, wide and filamentous compared to normal hairs. May see cuffs of arthrospores on 40x magnification.



Infected hairs (arrow) are wider and paler than normal hairs, seen here on 10x magnification.

PCR Assay for Highly Suspect Cases that are negative on Wood's lamp and direct exam:

Refer to page 4 of this protocol for instructions on how to obtain PCR samples.

Additional Testing:

Perform an FeLV test on ringworm suspects. If FeLV positive, ensure patient has been thoroughly examined for signs of active infection. Discuss case with the primary attending vet and the Director of Volunteer & Kitten Programs for case management.

Documentation:

Ensure animal's physical examination, Wood's lamp examination, and direct examination of hair are recorded thoroughly to serve as baselines for response to treatment. Ensure the location of visible hair lesions and Wood's lamp positive results are indicated on a body map.

Risk Assessment and Action Steps for Exposed Animals:

Highly suspicious cases (those with lesions and/or a known history of ringworm exposure but are negative on Wood's lamp and direct examination) should be started on oral and topical ringworm treatment while PCR results await.

Due to the highly contagious nature of ringworm and the increased susceptibility of kittens to acquiring ringworm, littermates of ringworm positive animals, because they have been meaningfully exposed, should be started on oral and topical ringworm treatment at the same time as their positive littermates and can remain housed with littermates.

Treatment:

A combination of topical and oral treatments is used to clear the infection as rapidly as possible. Topical treatment kills spores on the hair coat; oral treatment kills spores in the hair follicle. Topical treatment helps reduce environmental contamination by limiting the number of spores infected animals shed between applications. Oral treatment cures the animal of infection from inside-out.

Regular vaccination schedules should continue to be followed throughout the treatment duration (i.e. repeat FVRCP vaccinations and deworming every 2-3 weeks for kittens). Re-examination via physical and Wood’s lamp exams should occur at such appointments to ensure patients are clinically resolving in an expected fashion.

Topical treatment with Malaseb (or VetraSeb) shampoo 2-3 times per week until animal is cleared:

1. Shake the bottle of Malaseb.
2. Wear protective clothing and/gloves.
3. Ideally, use a flea comb to remove broken hairs from the animal’s coat before starting.
4. Dilute Malaseb to a 1:4 ratio with warm water. Try to soak the coat all the way to the skin.
5. Apply for a contact time of 3 minutes.
6. Use a cottonball or small rag to apply diluted Malaseb around the eyes, mouth, on and inside the ears as these are common sites of lesions.
7. Rinse and dry the animal.
8. Prevent hypothermia by wrapping the animal in a dry towel or blanket after bathing.

Additional topical focal treatment:

1. For areas that are harder to treat (face, ears), add in topical spot treatment once daily.
 - a. Carefully apply 1-2% miconazole or terbinafine topical ointment to lesions in these areas. Commercial preparations include Monistat and Lamisil.
2. Ensure that topical focal treatments are not used as sole therapy for affected animals.

Oral treatment with Itrafungol (refer to program veterinarian for dosing) for a 21-day course:

1. Pulse therapy using oral Itrafungol solution (refer to program veterinarian for dosing) once daily on alternating weeks for 3 treatment cycles. A total of 21 days of actual treatment is provided.

7 days	7 days	7 days	7 days	7 days
Daily treatment	No Treatment	Daily treatment	No Treatment	Daily treatment

2. Provide Itrafungol to all animals requiring treatment.
 - a. This medication can be used in kittens as small as 0.5 lbs.
 - b. Use with caution in pregnant/lactating cats.
3. Offer with a small meal of canned food to enhance absorption.
4. Kittens should be weighed weekly to accurately adjust their Itrafungol dosage.

Deciding when to stop treatment:

Always treat every ringworm positive animal for the full 21 day course of Itrafungol over the five-week period. Even after completing oral pulse therapy, continue Malaseb shampoos and topical focal treatment until the animal is cleared by a veterinarian (see below).

Over time, the animal should clinically cure and will need to be examined and tested for mycological cure. Infection will typically clear before lesions completely resolve and fur has regrown. In some animals, hair will fall out and lesions will look worse as they cure.

Determining cure includes physical examination of the animal and Wood’s lamp examination. Compare the animal’s initial clinical and diagnostic findings, including their initial lesions and Wood’s lamp positive results located on the original body map, to your final findings.

After an animal has been on treatment, a Wood's lamp examination is considered negative when the intrafollicular portion of the hair is negative and the majority of the hair shaft is negative. The distal tips of hairs may still fluoresce; however, this is common in cats that have recovered.

End points of treatment at 6 weeks include:

- Absence of lesions on physical exam & Wood's lamp negative → send sample to IDEXX for a PCR test (code 3565)* to confirm a NEGATIVE result (no longer active infection)

- Absence of lesions on physical exam but Wood's lamp positive:
 - a. If, on Wood's lamp, the intrafollicular portion of the hair is NOT fluorescing but the hair shaft and/or the hair tips are fluorescing → consider this a NEGATIVE result & perform an IDEXX PCR test (code 3565) to confirm there is no longer active infection
 - i. Bathe this animal one final time
 - b. If, on Wood's lamp, the intrafollicular portion of the hair is still fluorescing → consider this a POSITIVE result (active infection remains), send sample to IDEXX for a PCR test with reflex culture (code 3685), alert program veterinarian and program director. Together, a plan will be created to determine appropriate next steps for resolving this case and to ensure the foster home is not a recurring source of contamination.

***Diagnostic Sampling for IDEXX Ringworm RealPCR**

If no distinct lesions are present, use a soft bristle toothbrush to perform a thorough coat brushing until there are visible hairs with follicles in the bristles; no less than 30 strokes and include the face and ears. Submit the toothbrush in a sterile container or new ziplock plastic bag.

If lesions are present, comb and also pluck hairs. Comb the periphery of suspect lesions and pluck hair with follicles, lift or remove crusts and/or perform skin scrapings from the active border of suspect lesion. Plucked hairs and/or crusts can be submitted in a red-top tube or empty, sterile tube.

Keep specimens refrigerated.

If submitting a panel that includes a fungal culture (code 3685), please submit an additional specimen for culture.

Environmental decontamination:

Cleaning and disinfecting against ringworm should include thorough pre-cleaning and thorough disinfecting steps to remove spores from the environment or contaminated objects most effectively.

1. Pre-cleaning:
 - a. Mechanically remove gross debris such as hair, feces, litter, etc. by wiping, swiffing, or vacuuming. If vacuuming, change out the vacuum bag or discard the collected contents to prevent recontamination.
 - b. Apply a detergent product, such as soap, to produce a visibly clean surface. Rinse.
 - i. Rescue at 1:64 (2 oz/gallon) can be used if available.

2. Disinfecting:

- a. Liberally apply any over-the-counter (OTC) disinfectant that is labeled against *Trichophyton* spp. to the cleaned surface for a 10 minute contact time before wiping away.
 - i. Examples of effective OTC disinfectants that are safe around kittens include:
 1. Fantastik
 2. Formula 409
 3. Simple Green
 - ii. Alternatively, apply Rescue at 1:16 solution (8 oz/gallon) with a 10 minute contact time before wiping away.

The MOST IMPORTANT steps in this process are the first two; these are the steps that will eliminate most of the spores. The purpose of following up with a disinfectant is to remove any remaining spores after the first two steps of cleaning.

Cleaning supplies used in a contaminated area should be thoroughly cleaned and disinfected (using one of the products mentioned above) between use and dedicated for use only in that area.

For any laundry that may have been contaminated with ringworm: these can be readily decontaminated by putting them in the washer. Cold or hot water does not matter. What does matter is to use the longest cycle possible and ensure that that washer is not overloaded. This ensures that the laundry is effectively agitated to remove ringworm. Bleach is not needed, but ensure detergent is used. If available, add in Rescue concentrate at 1oz per gallon of washer capacity. Dry out in the sun or in the dryer on high temperature setting. Clean lint filters from the dryer after doing ringworm laundry.

Large porous objects which cannot be laundered (such as cat trees) should either be discarded or soaked in 8oz/gallon Rescue solution or 8 oz/gallon lime sulfur solution and allowed to air dry before reuse. Placing them outside may also aid in decontamination as UV light is known to kill ringworm spores.

Tips for discharging ringworm patients:

Items to provide to foster families:

- Malaseb or VetraSeb shampoo
- Itrafungol medication w/ dosing syringe
- Gowns/gloves
- Flea Comb

Instructions/advice to provide to foster families:

- Ringworm patients may live in your foster home for up to 6 weeks while they are being treated. Socialization of these kittens, especially since they will be with you for a prolonged period, is critical to the development of friendly and adoptable animals.
- House affected patients in an area that is easily disinfected.
- Use gloves when handling ringworm patients due to its contagious and zoonotic potential. Wash hands thoroughly after handling animals.
- Maintain a separate set of clothing when handling affected patients.